

## The Current Management of Intracranial Ependymomas in Children

**Bong-Soo Kim MD, Chanland Roonprapunt MD, Victoria LaMarca MS, Karl F Kothbauer MD, George I Jallo MD.** Division of Pediatric Neurosurgery, Institute for Neurology and Neurosurgery, Beth Israel Medical Center, New York, New York

### Abstract

**AIM:** The authors discuss the current management for intracranial ependymomas in children and young adults. Ependymomas are rare central nervous system neoplasms that account for a 1/3 of all posterior fossa tumors in children. There has been much controversy with the management of these tumors.

**METHODS:** Surgery can safely be performed using surgical adjuncts such as the ultrasonic aspirator and neurophysiological monitoring. The role of adjuvant chemotherapy and radiation therapy has yet to be determined.

**RESULTS:** A gross total resection of these tumors results in a good long-term outcome, since these tumors are relatively resistant to adjuvant therapy. Adjuvant radiation therapy should only be administered for the high grade or residual tumor. Tumors in young infants have a worse prognosis than older children.

**CONCLUSION:** Ependymomas are relatively aggressive tumors which are resistant to adjuvant therapies. A gross total resection, at first operation, should be attempted. Residual tumor should be treated with adjuvant therapy and second-look surgery.

**Keywords:** Brain · Central Nervous System · Ependymoma · Neoplasm · Tumor

### Introduction

Ependymomas are relatively rare neuroepithelial tumors and account for 3-7% of all central nervous system (CNS) tumors. Among pediatric CNS tumors, ependymomas are the third most common intracranial tumor (6-14%) after juvenile pilocytic astrocytomas and primitive neuroectodermal tumors. The incidence in children is reported to be six times that in adults. Fifty percent of them occur under the age of five years and approximately two thirds of them occur in the infratentorial compartment. Supratentorial ependymomas occur more frequently in adults (1, 4, 8, 14, 17, 23, 28, 34, 38, 46). Surgery is the mainstay of management, and an increasing rate of complete surgical resection has been reported in recent years. Ependymomas in the posterior fossa, particularly in children, are difficult to completely resect without significant morbidity. Postoperative

radiotherapy (RT) is believed to improve the prognosis of these tumors and most institutions indeed use RT as the primary adjuvant therapy for all intracranial ependymomas. Several trials of adjuvant chemotherapy have been reported, but most results have been disappointing (3, 9, 11, 35, 36, 41, 43). Although advances in diagnostic and management modalities have improved the outcome for other CNS pediatric tumors, the prognosis for intracranial ependymomas, particularly posterior fossa, remains dismal.

This article outlines the clinicopathological features of intracranial ependymomas in children and their optimal treatment strategies.

### Pathology

Ependymomas are presumably derived from the primitive neuroepithelial cells that line the ventri-

#### Correspondence:

George I. Jallo,  
M.D. Division of  
Pediatric  
Neurosurgery,  
Institute for  
Neurology and  
Neurosurgery,  
Beth Israel  
Medical Center,  
170 East End  
Avenue, New  
York, NY  
10028, USA  
Phone : 212-  
870-9600, Fax :  
212-870-9665,  
E-mail:  
gjallo@chpnet.org

cles. and the central canal of the spinal cord. There are several different histological variants of ependymomas that have been characterized, according to degree of anaplasia or cellular derivatives. The WHO grading system has recognized four basic ependymoma groups, broadly classified into several non-anaplastic forms and an aggressive anaplastic form. The WHO classification includes the classic ependymoma (with cellular, papillary, clear cell, and fibrillar or tancytic variants), subependymoma, myxopapillary ependymoma, and anaplastic ependymoma (21).

Classic ependymomas are solid, well-demarcated dark red tumors. Histologically, they are composed of columnar and astrocyte-like fibrillary cells arranged around a central lumen, resembling the ependymal epithelia, in the form of rosettes or perivascular pseudorosettes. Significant morphologic variability may be present, but this group of ependymomas are all considered WHO grade II tumors. Variant forms of ependymomas have been characterized by the presence of increased cellularity, papillary growth pattern, clear cell morphology or fibrillary/tancytic formation. These tumors will stain positive for glial fibrillary acidic protein (GFAP) to varying degrees. Electron microscope analysis may be necessary because of the significant variability in the histologic subtypes. The presence of either cilia or basal cell blepharoplasts confirms the diagnosis of ependymoma.

Subependymomas and myxopapillary ependymomas are slow-growing ependymomas classified as WHO grade I. Subependymomas are nodular and arise from within the ventricular wall, primarily from the fourth ventricle in about half the reported cases. They appear as tufts of cells within a fibrillary matrix and are believed to be derived from the subependymal glial cells. In contrast, myxopapillary ependymomas are almost exclusively found in the lower spinal canal around the conus, cauda equina, and filum terminale area. Histologically, this variant appears papillary with mucocystic cells around vascular networks. Myxopapillary ependymomas characteristically express GFAP, S100, and vimentin, but not cytokeratin.

Malignant or anaplastic ependymomas are given WHO grade III classification due to such histological features as pleomorphism (giant cell formation), endothelial hyperplasia, mitotic figures, vascular proliferation, and necrosis. This high-grade variant is locally invasive and subarachnoid dissemination may be found which portends to a poorer prognosis.

Molecular characterization of ependymomas has revealed significant heterogeneity. Several genetic

alterations have been characterized. The most common genetic aberrations that have been discovered involve chromosome 22. For example, mutations on 22q12 at the NF2 tumor suppressor gene locus have been correlated with spinal ependymomas. Other chromosomes implicated with ependymomas include chromosome 9, 10, 13, and 17.

### Clinical presentation

The clinical signs and symptoms of intracranial ependymomas depend on the location, size of the tumor, and the age of the patient. Ependymomas are typically large at time of presentation because they grow slowly. The symptoms for posterior fossa ependymomas are usually related to increased intracranial pressure from hydrocephalus caused by obstruction of the fourth ventricle. The most prominent presenting symptoms include nausea, vomiting, and headache. Ataxia, hemiparesis, dizziness, and visual disturbances are also seen frequently. The extension of the tumor into the cervical subarachnoid space may result in neck pain, nuchal rigidity, and torticollis. Children over the age of two years commonly present with vomiting, headache, papilledema, and ataxia. Common signs and symptoms in children under the age of two years are vomiting, lethargy, irritability, and failure to thrive(1, 8, 9).

Supratentorial ependymomas occur more frequently in older children and adults. Their signs and symptoms are primarily related to mass effect from the tumor. They typically present with focal neurologic deficits such as limb weakness and visual field defects(1, 28, 43, 46).

### Imaging characteristics

Ependymomas appear isodense or hyperdense to brain on precontrast computed tomography (CT). They have mild to moderate heterogenous enhancement with intravenous contrast. Calcification occurs in nearly 50% of all cases. In the posterior fossa, ependymomas typically present as solid masses in the fourth ventricle with extension through the foramen of Luschka into cerebellopontine (CP) angle or through the foramen magnum into cervical spinal canal (Figure 1 and 2). Supratentorial ependymomas have a more variable appearance with heterogenous enhancement after contrast administration (Figure 3). They tend to be cystic, calcified and well-demarcated tumors(2).

On magnetic resonance imaging (MRI), ependymomas may also have a variable appearance due to small cysts or calcifications. On T1-weighted imaging, ependymomas are hypointense as compared to brain parenchyma. On T2-weighted imaging, these tumors are isointense with gray matter. However,

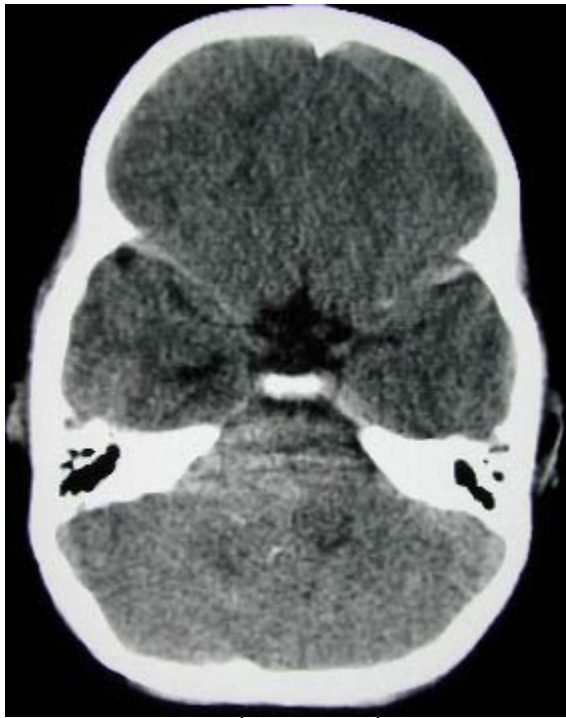

Figure 1a

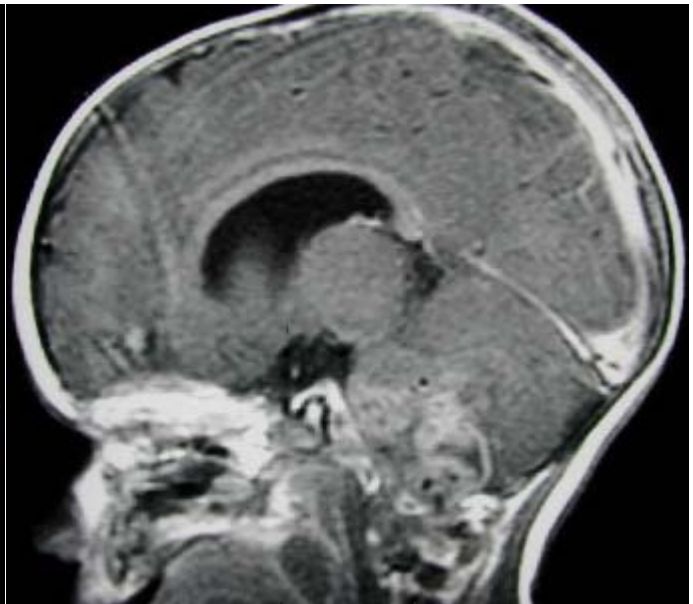


Figure 1c

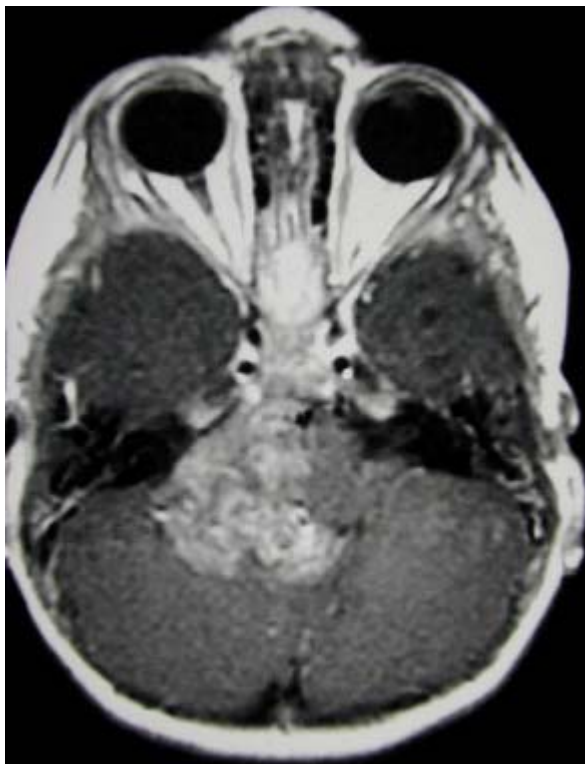


Figure 1b

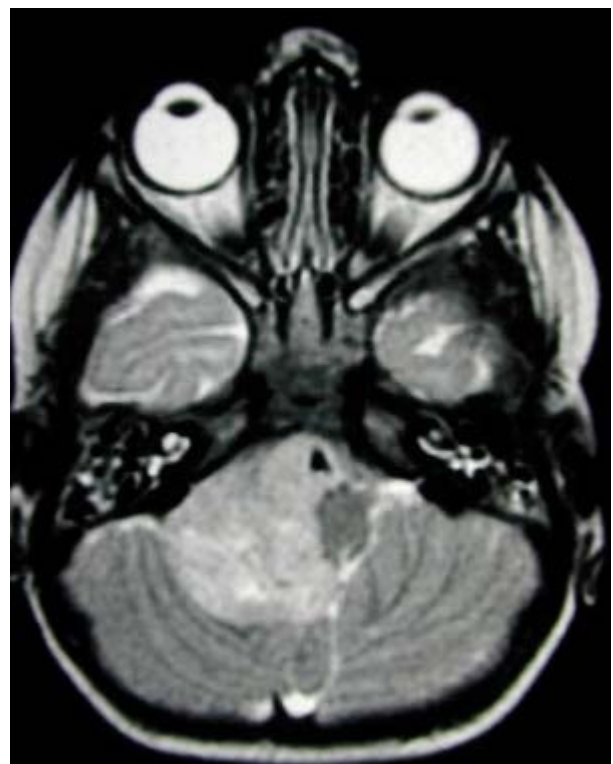

Figure 1d

**Figure 1:** Imaging characteristics for a fourth ventricle ependymoma with extension into the cerebellopontine cistern. (a) Noncontrast CT scan demonstrates a slightly hyperdense lesion within the cerebellopontine angle. (b) T1-weighted axial image with gadolinium demonstrates the location of the tumor lateral to the brainstem displacing the basilar artery. (c) T2-weighted axial image demonstrates the hyperintense signal characteristics. (d) T1-weighted sagittal image.

the diverse signal characteristics may make the diagnosis of ependymoma difficult on MRI.

The most characteristic finding to support a diagnosis for infratentorial ependymomas is

downward extension of the tumor through the foramen of Magendie into the cervical subarachnoid space or through the foramen of Luschka into the cerebellopontine cistern(2, 8, 9, 22).

**Treatment**

Despite great interest for pediatric intracranial ependymomas among neurosurgeons, neurooncologists, and radiotherapists, there is still considerable controversy regarding optimal management of intracranial ependymomas in children, and no standard protocol has been established.

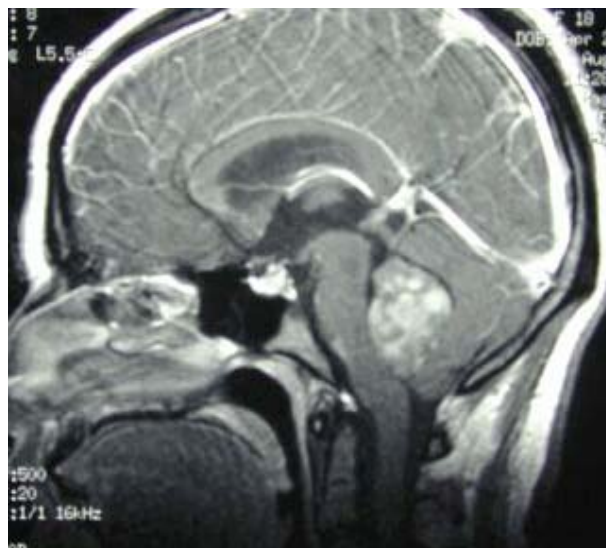

Figure 2c

**Figure 2:** A fourth ventricle ependymoma confined to the fourth ventricle. (a) T1-weighted axial image demonstrates a hypointense lesion within the fourth ventricle. (b) T1-weighted axial image with contrast demonstrates a heterogenous enhancement pattern. (c) T1-weighted sagittal image reveals the exact location within the fourth ventricle.

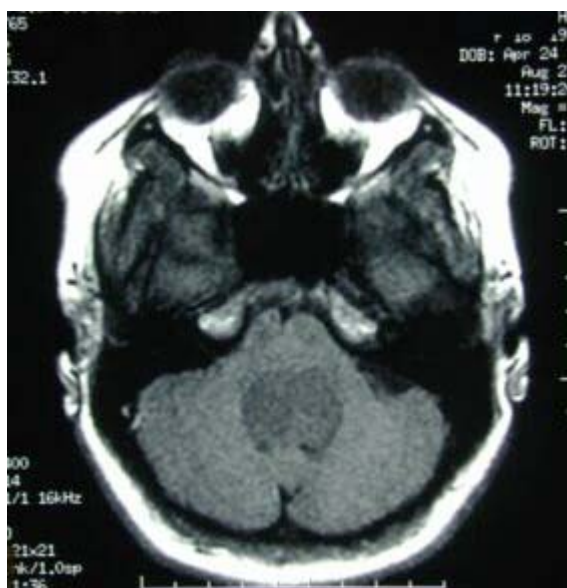


Figure 2a

**Surgery**

Surgery is the mainstay and the initial treatment for intracranial ependymomas in children. Many authors have emphasized the extent of tumor resection as a significant prognostic factor(7, 9, 26, 35, 36). Therefore, the best effort to perform total or near-total resection should be made. Technological advances such as the ultrasonic aspirator and neurophysiological monitoring allow for a total or near-total resection of tumor with minimal morbidity(9, 35). Review of the recent literature reveals that the rate of total resection for supratentorial ependymomas appears to be 53-72% and for infratentorial ependymoma 27-55%(4, 23-26, 28, 33, 35, 36, 43, 45).

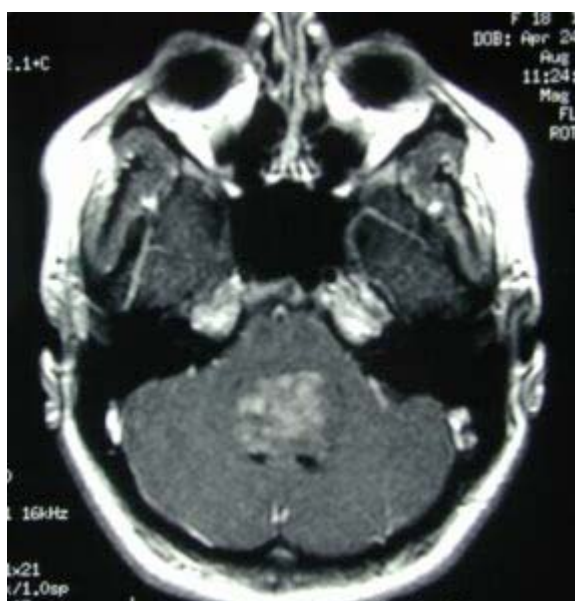

Figure 2b

**Infratentorial ependymomas**

The most common location for infratentorial ependymoma is within the fourth ventricle. The surgical approach, therefore, is a suboccipital craniotomy with or without C1 laminectomy, depending on the extent of the tumor in the cervical region. The dura is opened with a standard Y-shaped incision crossing the foramen magnum. Ependymomas often protrude through the foramen of Magendie into the cisterna magna and even downwards to the cervical spinal canal.

The tumor is soft and red-grey in color. The tumor, however, does not infiltrate the pia, and this portion of tumor can be removed without difficulty. The tumor in the fourth ventricle can be exposed by elevation of both tonsils. The inferior vermis may be elevated to provide the necessary exposure and opening the sulcus between the tonsil and vermis can provide wider access to the tumor without splitting the inferior vermis. This technique avoids splitting the inferior cerebellar vermis which may result in posterior fossa syndrome(5, 8). As early as possible the floor of fourth ventricle must be inspected and protected by placing a cottonoid strip. The majority of the tumor bulk is resected in piecemeal fashion using the bipolar cautery-suction and the cavitron ultrasonic aspirator (CUSA). The real challenge of ependymoma surgery is the management of the attachment to the floor of the fourth ventricle, which is the site of origin. The brainstem nuclei under the floor of fourth ventricle may not be displaced, therefore, an attempt to resect this attachment may result in significant postoperative morbidity, particularly lower cranial nerve dysfunction. It may be very frustrating for a neurosurgeon not to remove a small portion tumor after the large majority has been successfully resected. According to the authors' experience, it is essential to realize that the broad attachment to the floor of fourth ventricle can not be removed without morbidity(9). In some cases, the attachment of the ependymoma to the floor of fourth ventricle is very small and limited to the obex. It must always be recognized that attempts to resect this tumor may result in significant neurological deficits. Neuro-physiological mapping of the floor of fourth ventricle can be helpful in the decision making(9).

A postoperative MRI must be performed within 48 hours after surgery. The extent of resection must be evaluated. Second-look surgery has been recommended to maximize the extent of resection in cases of unexpected residual tumor or when the decision for a staged operation was made (13). Optimal timing of second-look surgery, however, is subject of debate. Some authors prefer a delayed second-look surgery after adjuvant chemotherapy or radiotherapy because adjuvant therapy may

reduce the tumor volume or alter its characteristics for improved surgical outcomes(12, 35). Since it is unclear that adjuvant therapy is beneficial, in cases where residual tumor is easily accessible with minimal morbidity, immediate second-look surgery might be a appropriate option to achieve radical resection of tumor(12).

Preoperative shunting, in the absence of clinically acute hydrocephalus, is no longer recommended because resection of the fourth ventricular tumor provides restoration of cerebrospinal fluid (CSF) pathways(9). Preoperative shunting can even be dangerous because it may predispose to upward herniation, intratumoral hemorrhage, postoperative subdural hematoma, and postoperative shunt-dependant state(8, 9, 41, 43). At least 80% of the patients will not need shunt placement after resection of a fourth ventricular ependymoma(43).

### **Supratentorial ependymomas**

Supratentorial ependymomas occur in either the ventricular system or a hemisphere and are usually large at time of diagnosis. The surgical approaches depend on the location and size of the tumor. Frameless image guidance, intraoperative MRI, and intraoperative ultrasound provide good localization of the tumor and facilitate resection of the tumor. Intraoperative neuroelectrophysiologic monitoring of motor and somatosensory evoked potentials minimize the morbidity.

## **ADJUVANT THERAPY**

### **Radiotherapy**

Postoperative radiotherapy (RT) has been considered the standard treatment for patients with intracranial ependymomas. Although no randomized trial has been conducted to evaluate the benefit of radiotherapy, several retrospective studies have reported a better prognosis for patients treated with postoperative RT compared to those treated with surgery alone(6, 24, 36, 39, 42). However, there is no consensus about postoperative RT for children who have a radiographically complete resection, particularly for children with supratentorial ependymomas because these tumors have a relatively well-defined margin and grow mainly by expansion(1, 7, 29, 43).

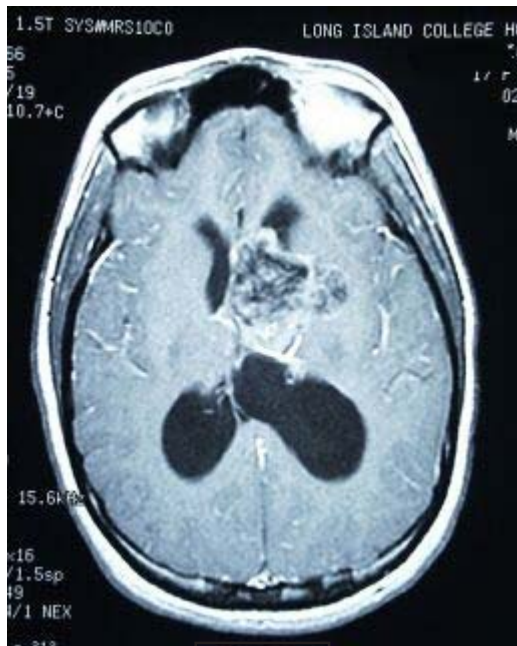

Figure 3a

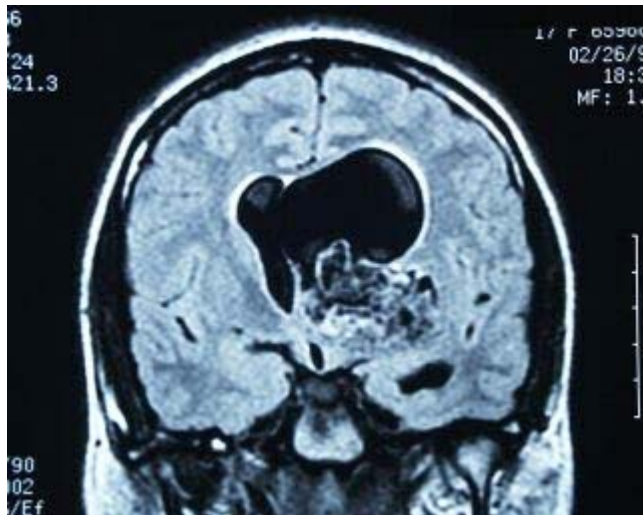


Figure 3b

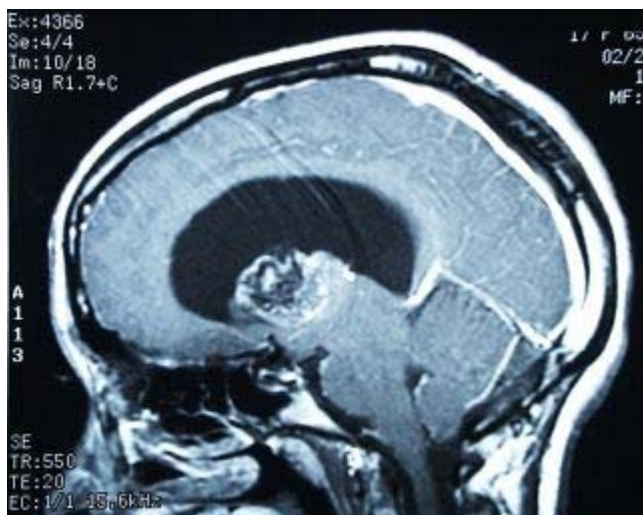

Figure 3c

**Figure 3:** A supratentorial ependymoma located in the left frontal horn. (a) T1-weighted axial image demonstrates a tumor within the left lateral ventricle and hydrocephalus. (b) Coronal MRI better demonstrates the origin of the tumor. (c) T1-weighted sagittal image demonstrates the heterogenous enhancement pattern typical for an ependymoma.

Despite general agreement of the efficacy of RT, there still is considerable controversy over the optimal volume of radiation (local field versus whole brain versus craniospinal axis). Most published reports recommend local field RT. The rationales are: relapse occurs at the primary tumor site, tendency of dissemination through the central nervous system is low, and there is no evidence that CNS seeding can be prevented by whole brain or craniospinal irradiation (4, 16, 20, 23-25, 33, 41, 43, 44). Protocols recommend 5400 cGy in 30 fractions over 6 weeks for low-grade ependymomas and 5940 cGy in 33 fractions over 6.5 weeks for high-grade ependymomas(4, 30, 31). The definition of “local field”, particularly for infratentorial ependymoma is not well defined. Some oncologists define it as the entire posterior fossa, whereas, others define local field as the tumor or tumor bed with a safety margin(16, 26, 30). Since smaller RT volumes, in particularly for children, may minimize the late adverse effects of RT, some retrospective studies have been conducted to determine the ideal volume. Paulino insisted that the appropriate and safe volume for non-disseminated and low-grade infratentorial ependymomas is the tumor bed with a 2-cm safety margin and does not need to include the entire posterior fossa(30).

Stereotactic Radiosurgery has been applied to manage recurrent or residual intracranial tumor in some institutions. Sanford et al. reported that in-field local control was achieved for 14 of 17 recurrent intracranial ependymomas and the 3-year local control rate was 68%. The study found that SRS provides good local tumor control for patients with recurrent disease and may have a favorable impact on survival(38). However, Hodgson et al. found that the 3-year local control in children with recurrent or residual intracranial ependymomas was only 29%(19).

### Chemotherapy

Despite considerable efforts with aggressive surgery and radiotherapy, the prognosis of intracranial ependymomas in children is still disappointing. Several studies, therefore, have been conducted to evaluate the efficacy of chemotherapy. Some reports have noted tumor responses and improved survival(27, 40), whereas most other studies have reported little effect of with chemotherapy on childhood ependymomas(3, 9, 11, 35, 36, 41, 43). Nevertheless, some studies demonstrated efficacy of chemotherapy in young children in an effort to postpone the postoperative radiotherapy(40, 41). Grill et al. reported that 40% and 23% of children under 5 years old were spared from radiotherapy at 2 and 4 years, respectively, after the initiation of chemotherapy. 74% of patients with radiologically complete resection and 35% of patients with incomplete resection survived for 4 years(15). A German prospective trial with 55 newly diagnosed anaplastic ependymomas in children described that adjuvant chemotherapy did not influence survival(42).

Although the role of adjuvant chemotherapy is a matter of debate, there is no convincing evidence that chemotherapy improves survival in children with intracranial ependymomas at the present time.

### Prognosis

The outcome of children with intracranial ependymomas has improved significantly during recent years. Their prognosis is poor when compared to the outcome for other pediatric brain tumors. Recent published reports demonstrate a 5-year overall survival rate of 40-65% for children with intracranial ependymomas(4, 11, 35, 36, 39, 40).

Many investigations have been conducted to find out prognostic factors for intracranial ependymomas, but all are retrospective include only a small number of cases.

The extent of surgical resection is the most significant prognostic factor in outcome for children with intracranial ependymomas(23, 26, 28, 43). In the review of published data, the overall 5-year survival rate for the patients with complete surgical resection is 60-80%,

compared to 22-41% for patients with incomplete surgical resection(11, 15, 23, 25-27, 35). CNS dissemination may occur more often in patients with incomplete surgical resection as compared to those with complete resection(33). Several investigators have reported a long survival and progression-free survival for patients with completely resected ependymoma without adjuvant therapy (26, 28).

Age of the patient at diagnosis is also an important independent factor. Young children with intracranial ependymomas have a significantly worse prognosis than older children. Healey et al. reported that the overall actuarial survival rate at 12 years for children younger than 24 months at diagnosis was 0% as compared to 62% for older children(18). Pollack et al. reported a 5-year overall survival rate of 22% in children younger than 3 years of age and 75% in children older than 3 years(32). Lyons et al. found the 5-year survival rates for patients with posterior fossa tumors was 14% for children and 76% for adults(23). It is not clear why young children have a worse prognosis than older children and adults. Some investigators report a higher incidence of high-grade ependymomas in the young children age group(10, 26). Also, these young children typically have infratentorial tumors which have a higher incidence for incomplete resection(23) (37). Young children, especially under 3 years old, have a disadvantage regarding adjuvant therapy. They are frequently treated with chemotherapy without postoperative radiotherapy(15, 40). Recently new protocols are under investigation to treat even young infants with radiation therapy.

It is controversial whether histopathology affects outcome. Ernestus et al., using a multivariate Cox Model analysis of 125 patients with intracranial ependymomas and the WHO grading system, found a statistically significant relevance of grading for the long-term prognosis of intracranial ependymomas. They reported a median progression-free survival (PFS) time of 7.5 years for Grade II, but 1.5 years for Grade III tumors(10). The histopathologic grade, however, did not significantly influence survival in other series. The possible explanation for this lack of histopathologic correlation to the outcome in intracranial ependymomas is the difficulty in

recognizing the anaplastic variant, because the common criteria for anaplasia are not completely reliable for ependymomas(24, 39). Therefore, there is no consistency regarding histological criteria for identifying anaplasia and the determination of anaplastic variant is not concise for all pathologists. Ependymomas are highly cellular tumors regardless of grade, and the high-grade tumors may be overdiagnosed(14, 24, 39, 43).

Several retrospective studies described that supratentorial ependymomas have a better prognosis than infratentorial ependymomas. The effect of the tumor location on the clinical outcome may result from the higher incidence of incomplete resection in the patients with infratentorial ependymomas(23, 37).

**Conclusion**

Ependymomas in children are difficult to control because of their resistance to adjuvant radiation and chemotherapy. Surgical resection remains the mainstay of treatment for these tumors. Infratentorial location and attachment to the floor of the fourth ventricle or brainstem often prevents complete removal, thus making recurrence more likely. In spite of progress in the surgical approach, radiotherapy options and chemotherapeutic agents, these tumors remain a therapeutic challenge because of their tendency to recur. New radiation therapy technology and chemotherapy agents are needed to be developed to help control this disease.

**References**

1. Applegate GL, Marymont MH: Intracranial ependymomas: a review. **Cancer Investigation** 16:588-593, 1998.
2. Barkovich AJ: *Pediatric Neuroimaging*. Philadelphia, Lippincott Williams & Wilkins, 2000.
3. Bouffet E, Foreman N: Chemotherapy for intracranial ependymomas. **Child's Nerv Syst** 15:563-570, 1999.
4. Bouffet E, Perilongo G, Canete A, Massimino M: Intracranial ependymomas in children: a critical review of prognostic factors and a plea for cooperation. **Medical and Pediatric Oncology** 30:319-331, 1998.

5. Dailey AT, McKhann GM, Berger MS: The pathophysiology of oral pharyngeal apraxia and mutism following posterior fossa tumor resection in children. **J Neurosurg** 83:467-475, 1995.
6. Donahue B, Steinfeld A: Intracranial ependymoma in the adult patient: successful treatment with surgery and radiotherapy. **J Neurooncol** 37:131-133, 1998.
7. Duffner PK, Krischer JP, Sanford RA, Horowitz ME, Burger PC, Cohen ME, Friedman HS, Kun LE: Prognostic factors in infants and very young children with intracranial ependymomas. **Pediatr Neurosurg** 28:215-222, 1998.
8. Duncan JA, Hoffman HJ: Intracranial Ependymomas, in Kaye AH, Laws ER (eds): *Brain Tumors*. Edinburgh, Churchill Livingstone, 1995, pp 493-504.
9. Epstein FJ, Goh KYC: Ependymomas of the posterior fossa, in A.H. K, Black PM (eds): *Operative Neurosurgery*. London, Churchill Livingstone, 2000, pp 429-436.
10. Ernestus RI, Schroder R, Stutzer H, Klug N: The clinical and prognostic relevant grading in intracranial ependymomas. **Br J Neurosurg** 11:421-428, 1997.
11. Evans AE, Anderson JR, Lefkowitz-Boudreaux IB, Finlay JL: Adjuvant chemotherapy of childhood posterior fossa ependymoma: cranio-spinal irradiation with or without adjuvant CCNU, vincristine, and prednisone: a childrens cancer group study. **Med and Ped Oncology** 27:8-14, 1996.
12. Foreman NK, Bouffet E: Ependymomas in children (Comment. Letter). **J Neurosurg** 90:605, 1999.
13. Foreman NK, Love S, Gill SS, Coakham HB: Second-look surgery for incompletely resected fourth ventricle ependymomas: technical case report. **Neurosurgery** 40:856-860, 1997.
14. Gerszten PC, Pollack IF, Martinez AJ, Lo KH, Janosky J, Albright AL: Intracranial ependymomas of childhood: lack of correlation of histopathology and clinical outcome. **Path Res Pract** 192:515-522, 1996.
15. Grill J, Deley ML, Gambarelli D, Raquin MA, Couanet D, Pierre-Kahn A, Habrand JL, Doz F: Postoperative chemotherapy without irradiation for ependymomas in children under 5 years of age: a

- multicenter trial of the French Society of pediatric oncology. **J Clin Oncol** 19:1288-1296, 2001.
16. Grill J, Renaux VK, Bulteau C, Viguier D, Levy-Piebois C, Sante-Rose C, Dellatolas G, Raquin MA, Jambaque I, Kalifa C: Long-term intellectual outcome in children with posterior fossa tumors according to radiation dose and volumes. **Int J Radiation Oncology Biol Phys** 45:137-145, 1999.
  17. Hamilton RL, Pollack IF: The molecular biology of ependymomas. **Brain Pathology** 7:807-822, 1997.
  18. Healey EA, Barnes PD, Kupsy WJ, Scott RM, Sallan SE, Black PM, Tarbell NJ: The prognostic significance of postoperative residual tumor in ependymoma. **Neurosurgery** 28:666-672, 1991.
  19. Hodgson DC, Goumnerova LC, Loeffler JS, Dutton S, Black PM, Alexander E, Xu R, Kooy H, Silver B, Tarbell NJ: Radiosurgery in the management of pediatric brain tumors. **Int J Radiation Oncology Biol Phys** 50:929-935, 2001.
  20. Horn B, Heideman R, Geyer R, Pollack I, Packer R, Goldwein J, Tomita T, Schomberg P, Ater J, Luchman-Jones L, Rivlin K, Lamborn K, Prados M, Bollen A, Berger M, Dahl G, McNeil E, Patterson K, Shaw D, Kubalik M, Russo C: A multiple-institutional retrospective study of intracranial ependymomas in children: identification of risk factors. **J Pediatr Hematol Oncol** 21:203-211, 2000.
  21. Kleihues P, Cavenee WK: Ependymal Tumors, in Kleihues P, Cavenee WK (eds): *World Health Organization Classification of Tumours. Pathology & Genetics. Tumors of the Nervous System*. Lyon, IARC Press, 2000, pp 71-80.
  22. Lefton DR, Pinto RS, Martin SW: MRI features of intracranial and spinal ependymomas. **Pediatr Neurosurg** 28:97-105, 1998.
  23. Lyons MK, Kelly PJ: Posterior fossa ependymomas: report of 30 cases and review of the literature. **Neurosurgery** 28:659-665, 1991.
  24. McLaughlin MP, Marcus RB, Buatti JM, McCollough WM, Mickle JP, Kedar A, Maria BL, Million RR: Ependymoma: results, prognostic factors and treatment recommendations. **Int J Radiation Oncology Biol Phys** 40:845-850, 1998.
  25. Merchant TE, Haida T, Wang MH, Finlay JL, Leibel SA: Anaplastic ependymoma: treatment of pediatric patients with or without craniospinal radiation therapy. **J Neurosurg** 86:943-949, 1997.
  26. Nazar GB, Hoffman HJ, Becker LE, Jenkin D, Humphreys RP, Hendrick B: Infratentorial ependymomas in childhood: prognostic factors and treatment. **J Neurosurg** 72:408-417, 1990.
  27. Needle MN, Goldwein JW, Grass J, Cnaan A, Bergman I, Molloy P, Sutton L, Zhao H, Garvin JH, Philips PC: Adjuvant chemotherapy for the treatment of intracranial ependymoma of childhood. **Cancer Investigation** 80:341-347, 1997.
  28. Palma L, Celli P, Cantore G: Supratentorial ependymomas of the first two decades of life: long-term follow-up of 20 cases (including two subependymomas). **Neurosurgery** 32:169-175, 1993.
  29. Palma L, Celli P, Mariottini A, Zalaffi A, Schettini G: The importance of surgery in supratentorial ependymomas. **Child's Nerv Syst** 16:170-175, 2000.
  30. Paulino AC: The local field in infratentorial ependymoma: does the entire posterior fossa need to be treated? **Int J Radiation Oncology Biol Phys** 49:757-761, 2001.
  31. Paulino AC, Wen BC: The significance of radiotherapy treatment duration in intracranial ependymoma. **Int J Radiation Oncology Biol Phys** 47:585-589, 2000.
  32. Pollack IF, Gerszten PC, Martinez AJ, Lo KH, Shultz B, Albright AL, Janosky J, Deutsch M: Intracranial ependymomas of childhood: long-term outcome and prognostic factors. **Neurosurgery** 37:655-667, 1995.
  33. Rezai AR, Woo HH, Lee M, Cohen H, Zagzag D, Epstein FJ: Disseminated ependymoma of the central nervous system. **J Neurosurg** 85:618-624, 1996.
  34. Robertson PL: Pediatric brain tumors. **Oncology** 25:323-339, 1998.
  35. Robertson PL, Zeltzer PM, Boyett JM, Rorke LB, Allen JC, Geyer JR, Stanley P, Li H, Albright L, McQuire-Cullen P, Finlay JL, Stevens K, Milstein J, Packer RJ, Wisoff J, Group CsC: Survival and prognostic factors following radiation therapy and chemotherapy for ependymomas in children: a report of the Children's Cancer Group. **J Neurosurg** 88:695-703, 1998.

36. Rousseau P, Habrand JL, Sarrazin D, Kalifa C, Terrier-Lacombe MJ, Rekeciewicz C, Rey A: Treatment of intracranial ependymomas of children: review of a 15-year experience. **Int J Radiation Oncology Biol Phys** 28:381-386, 1994.
37. Sala F, Talacchi A, Mazza C, Prisco R, Ghimenton C, Bricolo A: Prognostic factors in childhood intracranial ependymomas: the role of age and tumor location. **Pediatr Neurosurg** 28:135-142, 1998.
38. Sanford RA, Gajjar A: Ependymomas. **Clin Neurosurg** 44:559-570, 1997.
39. Schiffer D, Giordana MT: Prognosis of ependymoma. **Child's Nerv Syst** 14:357-361, 1998.
40. Souweidane MM, Bouffet E, Finlay J: The role of chemotherapy in newly diagnosed ependymoma of childhood. **Pediatr Neurosurg** 28:273-278, 1998.
41. Sutton LN, Goldwein JW, Schwartz D: Ependymomas, in Albright AL, Pollack IF, Adelson PD (eds): *Principles and Practice of Pediatric Neurosurgery*. New York, Thieme, 1999, pp 609-628.
42. Timmermann B, Hortmann RD, Huhl J, Meisner C, Slavic I, Pietsch T, Bamberg M: Combined postoperative irradiation and chemotherapy for anaplastic ependymomas in childhood: results of the German prospective trials HIT 88/89 and HIT 91. **Int J Radiation Oncology Biol Phys** 46:287-295, 2000.
43. Tomita T: Ependymomas, in McLone DG (ed) *Pediatric Neurosurgery*. Philadelphia, WB Saunders, 2001, pp 822-834.
44. Vanuytsel L, Brada M: The role of prophylactic spinal irradiation in localized intracranial ependymoma. **Int J Radiation Oncology Biol Phys** 21:825-830, 1991.
45. Vinchon M, Soto-Ares G, Riffaud L, Ruchoux MM, Dhellemmes P: Supratentorial ependymoma in children. **Pediatr Neurosurg** 34:77-87, 2000.
46. Wiestler OD, Schiffer D, Coons SW, Prayson RA, Rosenblum MK: Ependymomas, in Kleihues P, Cavenee WK (eds): *Pathology & Genetics of Tumors of the Nervous System*. Lyon, IARC Press, 2000, pp 71-80.

## Disclaimer

**While every effort has been made by the publisher, editor, editorial board to make certain that there are no inaccuracies in this journal, statements, opinions, data, figures appearing in the articles herein are the responsibility of the authors concerned. The Information on this journal are published for physicians only.**